

# Female Patient with Severe Upper Abdominal Pain – A Case Report

Abdul Basit, Abdul Waseh, Abdullah Faisal, Abdullah Haroon, Ahmed, Abeeha Javed, Alishba Akram, Hajra Fayyaz, Laiba Ejaz, Ayesha Asim, Ayesha Ahmed, Hajjra Iftakhar, Fizza Amjad, Ayesha Fatima, Ayesha Zahid, Hajera Awais, Haleema

1st Year MBBS, Islamabad Medical and Dental College, Islamabad, Pakistan

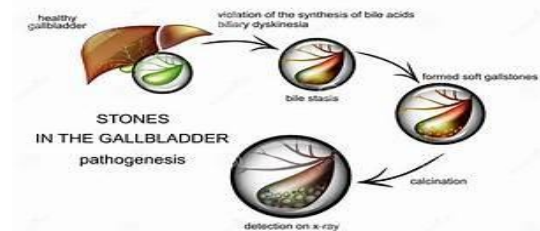
## ABSTRACT

Cholelithiasis is the medical term for the presence of gallstones in the gallbladder. Gallstones are solid particles that form in the gallbladder, a small organ beneath the liver that stores bile, which helps digest fats. While often asymptomatic, it can lead to significant morbidity when symptomatic. The main features observed clinically in this condition include severe abdominal pain radiating towards chest, nausea, vomiting, fever, chills, bloating, clay-colored stools and dark urine. Here we present a case of a 38-year-old female with severe pain in her upper abdomen radiating towards her back along with vomiting, nausea and dysuria with dark bloody urine and low-grade fever. CBC, LFT, Lipase serum test and upper abdominal ultrasound are the common test related to presented symptoms which were performed on the patient. The doctor quickly identified it as gallbladder-related pain and started her on medications which resulted in a successful outcome. In general gall stones are also more prevalent in males than females after age of 40 years.

**Key Words:** *Abdominal pain, Dysuria, CBC, LFT, Lipase serum test, Gall stones, Gall bladder, Ultrasonography, Cholecystectomy*

## Introduction

Cholelithiasis, commonly referred as gall stones is a condition of having hardened, crystallized deposits or stones in gall bladder and bile duct. They are formed from hardened components of bile primarily including cholesterol, bilirubin and bile salts. Gallstones vary in size and number, ranging from tiny grains to several centimeters in diameter. Many patients are asymptomatic but the most common symptoms are biliary colic (sudden pain in upper right quadrant), nausea, vomiting, indigestion and jaundice. Gall stones of obstruct the bile flow can lead to several complications like inflammation of gall bladder (cholecystitis), pancreatitis and bile duct inflammation (cholangitis). It is mostly diagnosed by abdominal ultrasound which is a highly accurate imaging technique. It is more prevalent in western countries especially in places like the United States and Canada, where diets high in fat and low in fiber, along with sedentary lifestyles, play a big role. Its low prevalence regions include Africa and some parts of Asia.



**Figure 1:** Figure showing pathogenesis of gall stones

## Patient Information

A 38 year old women is presented in emergency with severe stomach pain. She had following symptoms from few weeks;

- Severe stomach pain for last 2 days
- Vomiting for last 1 day
- Constipation for last few days
- Nausea

- Swelling on feet for last 7-8 days
- Dysuria with dark , bloody urine
- Joint pain and hair loss
- Low grade fever at night 1:00-2:00

**Physical Examination**

Following physical examinations were done when she was being examined ;

- Chest pain
- Joint pain
- Dark urine with blood that causes irritation after urination
- Abdominal pain travelling towards the chest

**Diagnosis Methods/Tests**

Following tests were performed to further examine about the problem;

- CBC,LFT , Lipase serum, Amylase serum tests by the Department of Pathology

• **Test Results**

**CBC**

Parameter	Result	Reference Range
WBC count	13030	4000-11000
RBC count	4.57	4-5.5
Platelets	242000	14000-450000

**LFT**

Chemistry	Result	Reference Range
Total bilirubin	0.80	0.2-1.1
ALT	33	65-240
ALP	101	65-240

**LIPASE SERUM TEST**

Chemistry	Result	Reference Range
Lipase serum	29.0	<62

**1.Upper Abdomen ultrasound report**

- **Liver:**
- It is normal in size (14.4 cm) and shape. It shows smooth margins and normal echotexture. No focal lesion is seen.

- No dilated intrahepatic biliary channels are seen. Portal vein is normal in calibre.

• **Gallbladder:**

- It is over distended at the time of scan, measuring approximately 45 ml with no mass, calculus or thickening of its wall seen in visualized lumen. No fluid collection is seen around it. No dilatation of intra or extra hepatic biliary channels noted. CBD is of normal calibre.

• **Pancreas:**

- It shows normal echotexture. No mass/ focal lesion is seen. Pancreatic duct is normal in calibre.

• **Spleen:**

- It is normal in size (9.2 cm) and echotexture. No focal lesion is seen.

• **Rt. Kidney:**

- Normal in size (10.7 x 4.9 x 1.6 cm), shape and echotexture. No mass, cyst, calculus or hydronephrosis is seen. Rt. ureter is not dilated

• **Lt. Kidney:**

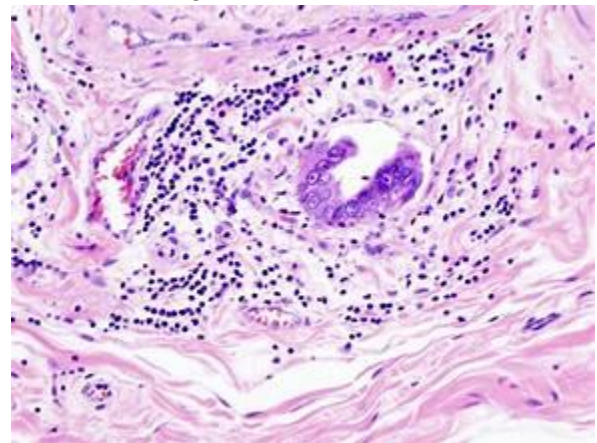
- Normal in size (10.6 x 4.0 x 1.3 cm), shape and echotexture. No mass,cyst,calculus or hydronephrosis is seen. Lt.Ureter is not dilated.

- **Urinary Bladder:** It is empty at the time of scan. No ascites detected.

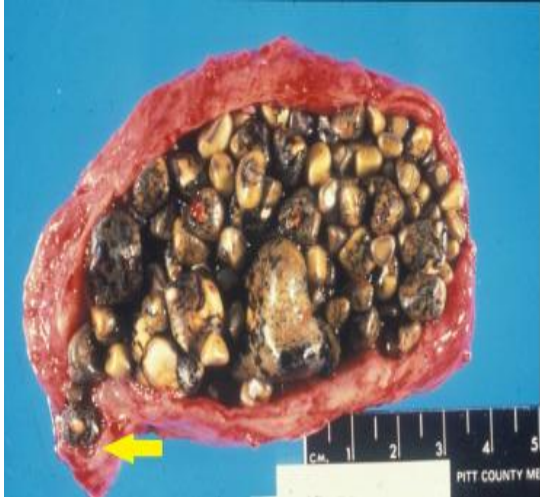- No Abdominal adenolymphopathy is seen.

• **Impression:**

**Over distended gall bladder**



**Figure 2:** Histological sections showing inflammatory changes, fibrosis and hyperplasia of gall bladder



**Figure 3:** Postoperative picture of gallstones

### Discussion

The most common and effective treatment for symptomatic gallstones is cholecystectomy, which involves the surgical removal of the gallbladder. This is typically performed using a laparoscopic (minimally invasive) approach, offering quicker recovery, less postoperative pain, and shorter hospital stays compared to open surgery.

Laparoscopic cholecystectomy is considered the gold standard for managing uncomplicated gallstone disease, especially in cases of biliary colic or gallbladder inflammation (cholecystitis). For patients who are not good surgical candidates due to age or comorbidities, non-surgical options may be considered:

Oral bile acid therapy (e.g., ursodeoxycholic acid) can help dissolve cholesterol stones, but it's slow (months to years), only works for certain types of stones, and stones often recur.

Extracorporeal shock wave lithotripsy (ESWL) may be used in select cases to break stones into smaller fragments, though it is rarely used today.

The people most at risk of bile stones is people suffering from obesity and also its gender dependant as well as it affects women more. According to the European Association of Urology (EAU) and the American College of Gastroenterology (ACG) guidelines, cholecystectomy is

recommended for patients with symptomatic gallstones, Gallstone- related complications (e.g., cholecystitis, pancreatitis, or choledocholithiasis) and Large gallstones or porcelain gallbladder due to increased cancer risk.

### Conclusion

Gallstones are a highly treatable disease with various ways of diagnosis and treatment however; the most common and suitable treatment is cystolitholapxy. Gall stones are also more prevalent in males than females after 40.

Written and oral consent was given by the patient for this case report

### References

1. European Association of Urology (EAU) Guidelines on Urolithiasis. 2023.
2. Parra-Landazury NM, Cordova-Gallardo J, Méndez-Sánchez N. Obesity and gallstones. *Visceral medicine*. 2021 Oct 7;37(5):394-402.
3. Lammert F. Gallstones: The thing in itself. *Clinical Liver Disease*. 2022 Nov;20:57-72







